

## FACTORS LEADING TO THE DEVELOPMENT OF ENDOMETRIAL HYPERPLASIA IN WOMEN OF REPRODUCTIVE AGE (A REVIEW)

**Dustova Nigora Kakhramonovna**

**Kurbonova Gulnora Radzhabovna**

Bukhara, Uzbekistan, postal code 200100

Bukhara State Medical Institute named after Abu Ali ibn Sina, Uzbekistan,  
Bukhara, A.Gijduvan str.1 Tel: +998(65) 223-00-50 e-mail: info@bsmi.uz,  
nigora\_dustova@bk.ru

<https://orcid.org/0000-0003-0707-5673>

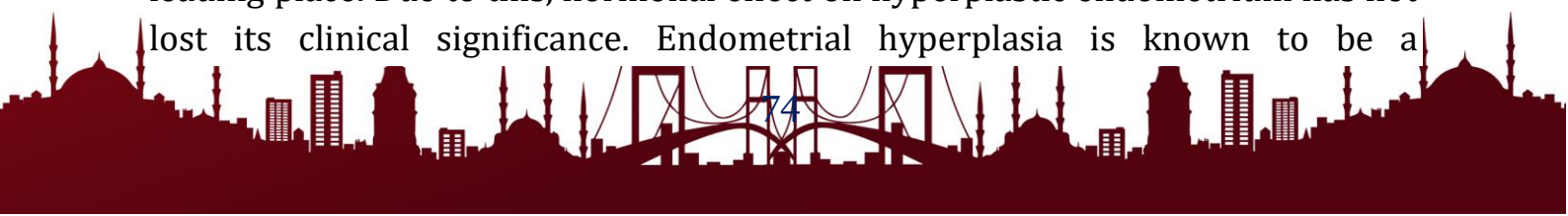
<https://doi.org/10.5281/zenodo.14500989>

**Abstract.** Despite the progress made in the study of etiopathogenesis, new methods for diagnosing and treating endometrial hyperplasia, the problem of treating patients with this pathology still remains far from being solved. All this dictates the need to optimize the tactics of managing patients with endometrial hyperplasia in reproductive age, which should be aimed not only at creating adequate comprehensive approaches to predicting the development and recurrence of endometrial hyperplasia, but also at developing uniform protocols for managing patients with this pathology. Key words: Endometrial hyperplasia, abnormal uterine bleeding, hyperestrogenism, proliferation, apoptosis.

### INTRODUCTION

Endometrial hyperplasia (EH) is a benign pathological process of the uterine mucosa, characterized by proliferation (growth) of the glands and an increase in the glandular-stromal ratio (the ratio of glandular and stromal cells). The main characteristic feature of the disease is the growth of the inner layer of the uterus - the endometrium, leading to a thickening and increase in its volume.

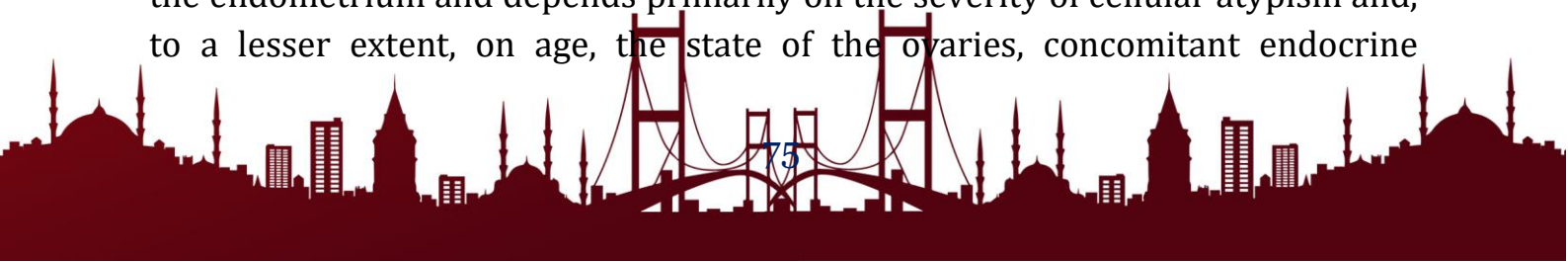
Hyperplastic processes of the endometrium are still of great scientific, medical and social significance in terms of the frequency of occurrence, disorders of the reproductive system and the lack of adequate methods of treatment [1,2,3]. Abnormal uterine bleeding, which is the most common clinical manifestation of endometrial hyperplasia, is the most common reason for visiting a gynecologist and ranks second among gynecological problems associated with referring a woman to hospitalization [4,5]. The issues of treatment of patients with endometrial hyperplasia cover a wide range of conservative and surgical methods. However, young women who want to preserve their reproductive function (in the absence of cellular atypia), conservative therapy is relevant, among which hormonal therapy takes the leading place. Due to this, hormonal effect on hyperplastic endometrium has not lost its clinical significance. Endometrial hyperplasia is known to be a



consequence of absolute or relative hyperestrogenism and progesterone deficiency, which leads to excessive (uncontrolled) cell division and reduced apoptosis [6,7].

The classic therapy for endometrial hyperplasia (EH) is the administration of progestins to counteract estrogenic influence. Progesterone has an antiproliferative effect on the mitotic activity of endometrial cells. Progestins reduce the number of estrogen receptors and accelerate their catabolism by stimulating 17-beta-hydroxysteroid dehydrogenase and sulfotransferase, and thus reduce estrogen dominance in the hormonal background, leading to endometrial hyperplasia [8]. However, recent reports of clinical studies have shown side effects of these drugs with long-term use, which is associated with their androgenic activity: an increase in plasma insulin concentration, a decrease in serum HDL levels, an increase in LDL, vasoconstriction, blocking the action of NO synthetase, etc. [9].

At present, based on the analysis of the work of gynecological hospitals, it is important to develop the basis for determining a medical strategy in the treatment of GE in relation to the choice of a conservative method of treating women of reproductive age. In this direction, it seems promising to take into account psychosomatic disorders, the frequency of which ranges from 30% to 57% of the total number of women applying to antenatal clinics [10,11]. Hyperplastic processes in the endometrium are a large group of histological changes in the glands and stroma of the endometrium, which are the basis for the formation of neoplastic processes in the uterus. One of the most significant factors with which the risk of developing this pathology is directly associated is the perimenopausal period, when the frequency of hormone-dependent pathology increases. Hyperplastic processes in the endometrium are one of the most common causes of uterine bleeding and hospitalization. The question of the risk of developing malignant transformation of HE remains open [1,2]. According to domestic and foreign studies, the degree of risk of malignancy of various HPE variants is determined by the morphological state of the endometrium and depends primarily on the severity of cellular atypism and, to a lesser extent, on age, ovarian condition, concomitant endocrine diseases, and other factors [4]. It has been proven that histopathological and molecular changes reflect the possible risk of transition of HE to EC. The degree of risk of malignancy of various HPE variants is determined by the morphological state of the endometrium and depends primarily on the severity of cellular atypism and, to a lesser extent, on age, the state of the ovaries, concomitant endocrine



diseases, and other factors [4]. It has been proven that histopathological and molecular changes reflect the possible risk of transition of HE to EC. The degree of risk of malignancy of various HPE variants is determined by the morphological state of the endometrium and depends primarily on the severity of cellular atypism and, to a lesser extent, on age, the state of the ovaries, concomitant endocrine diseases, and other factors [4]. It has been proven that histopathological and molecular changes reflect the possible risk of transition of HE to EC.

The complexity of the etiopathogenesis of HPE creates significant difficulties in the choice of treatment methods. This can explain the lack of uniform recommendations on the choice of a drug, the dose and the optimal duration of its use, which is often inadequate, and therefore, one has to deal with relapses of HE [5]. Recurrent uterine bleeding, oncological alertness in long-term proliferative processes against the background of concomitant pathology, dictate the need for more active management of this group of patients [6]. Thus, despite the progress made in the study of etiopathogenesis, new methods for diagnosing and treating HPE, the problem of treating patients with this pathology still remains far from being solved.

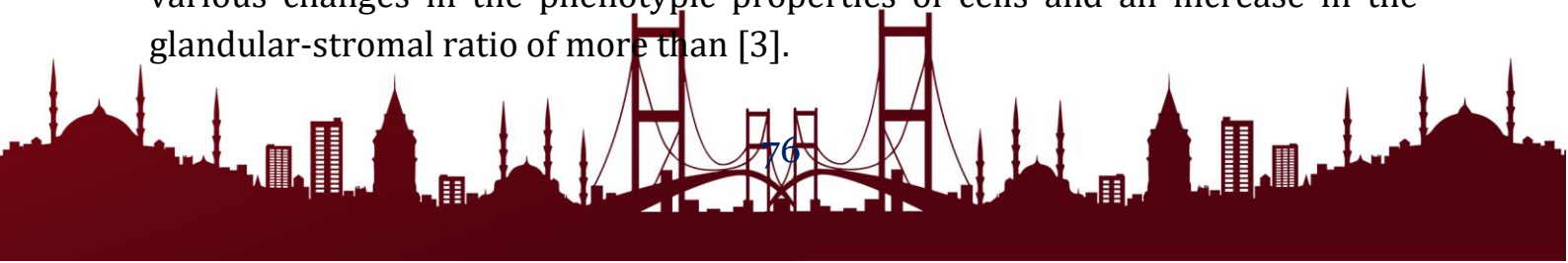
#### **THE PURPOSE OF OUR RESEARCH**

The aim of this study was to study the causes of recurrent endometrial hyperplastic processes in women of reproductive age.

#### **RESULTS AND DISCUSSIONS.**

The problem of endometrial hyperplastic processes (HPE) in women of reproductive age is one of the urgent problems of gynecology due to the high prevalence of this pathology in women of this age [11,12]. The unrelenting interest in it is determined by the tendency of HPE to a long, recurrent course, the absence of specific, pathognomonic symptoms, the complexity of differential diagnosis and the choice of treatment methods [13,14]. The endometrium, the inner glandular layer of the uterus, is a dynamic tissue that undergoes a series of changes during the menstrual cycle during a woman's reproductive years [1]. The delicate balance between endometrial proliferation and apoptosis is maintained by a complex process involving a number of factors: hormonal balance, molecular mechanisms, environment, age, and so on.

One of these gynecological diseases is endometrial hyperplasia (EH), which is characterized by non-physiological proliferation of endometrial glands with various changes in the phenotypic properties of cells and an increase in the glandular-stromal ratio of more than [3].

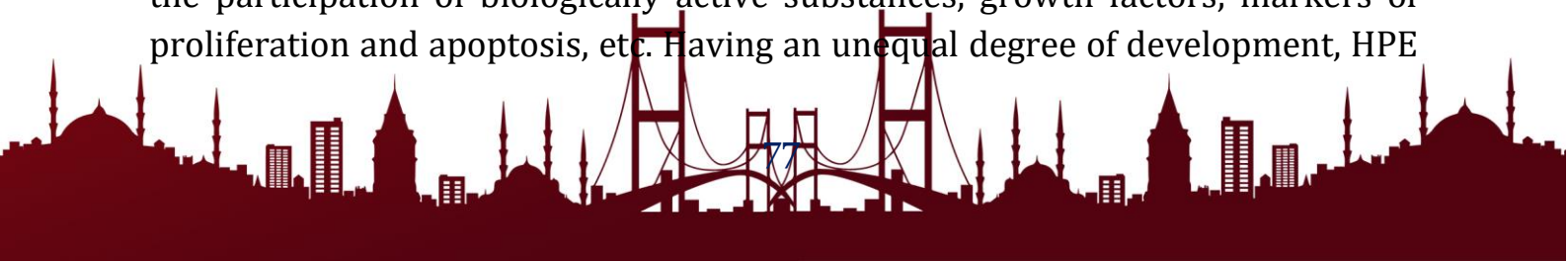

The prevalence of endometrial hyperplastic processes among gynecological diseases ranges from 10 to 50%, which is constantly growing [4]. According to the literature data, in Western Europe there are about 200,000 new cases of endometrial hyperplasia per year [5]. The need for hospitalization for surgical treatment and a decrease in the quality of life retain the significance of the problem of HE [6]. About 40% of young women with endometrial hyperplasia undergo intrauterine interventions, which may be the cause of infertility in women of the reproductive period [7].

Proliferative diseases of the endometrium, according to modern concepts, are defined as a complex of morphological lesions from benign to malignant, mediated by a transitional preinvasive stage [8]. In fact, they form a heterogeneous group of pathological processes: from normal polyclonal endometrium, which responds to abnormal hormonal influences, to proliferative monoclonal lesions that occur focally and are accompanied by a high risk of endometrial cancer (EC) [9]. In this connection, it is important to focus on precancerous lesions of the endometrium, which are a characteristic sequence of pathomorphological processes [16].

According to official data for 2019 in Russia, the prevalence of endometrial cancer (EC) is 27,151 cases, which is about 8% of the total incidence of malignant neoplasms in the female population [10]. In 2021, Western colleagues registered more than 66,570 newly diagnosed cases of EC in women and more than 12,940 deaths from this disease, which ranks 4th among all cancers in women. It was also noted that every year the incidence of endometrial cancer increases by 1%, and mortality by 2%. According to the American Cancer Society, an estimated 70% of uterine cancers are associated with overweight and lack of physical activity and, therefore, are potentially preventable [11].


According to RCTs, approximately 6.5% of patients who were diagnosed with HE were aged 20 to 44 years, and 70-88% did not give birth [12]. However, it has been noted that the incidence of endometrial hyperplasia is three times higher than the incidence of endometrial cancer [13]. From the modern point of view, HE is considered as a polyetiological pathological process, the development and progression of which can be facilitated by many different reasons [17]. The pathogenesis of HPE is characterized by a complex interaction of systemic processes (neuroendocrine, metabolic and immune) and local changes (receptor status and genetic apparatus of endometrial cells), as well as the participation of biologically active substances, growth factors, markers of proliferation and apoptosis, etc. Having an unequal degree of development, HPE



often become a favorable background for the occurrence of precancer, and then endometrial cancer (EC) [18]. The question of the risk of developing malignant transformation of HE remains open [19]. According to domestic and foreign studies, the degree of risk of malignancy of various HPE variants is determined by the morphological state of the endometrium and depends primarily on the severity of cellular atypism and, to a lesser extent, on age, the state of the ovaries, concomitant endocrine diseases, and other factors [20]. It has been proven that histopathological and molecular changes reflect the possible risk of transition of HE to EC. Despite the fact that HE is considered as a risk factor or precursor of uterine cancer, which is given rather modest attention to this problem, as evidenced by the lack of serious monographs, modern randomized placebo-controlled studies, relatively few original articles. At the same time, many unresolved issues have accumulated that require scientific coverage and further development. Approximately one third of women of reproductive age seek medical attention for abnormal uterine bleeding associated with GE.

The problem of recurrence of endometrial hyperplasia is acute in modern medicine and requires more detailed study. According to the literature, a significant percentage of patients do not respond to conservative treatment or show relapse after remission with the risk of developing EC [18]. For this reason, in recent years there has been a growing interest in the study of clinical, imaging, histological and molecular factors that may affect the outcome of therapy [19-21]. Immunohistochemistry is the most commonly used tool in the evaluation of tissue markers for the diagnosis, prognosis and treatment of a large number of diseases and has played an important role in this field [22].

Estrogen receptors a and b (ERa and ERb) Estrogens bind to one of two nuclear receptors (E1a and EK|3), which are both encoded by independent genes. The receptors act as ligand-dependent transcription factors with subsequent modulation of gene expression. Studies have proven the importance of estrogens in the regulation of endometrial cell proliferation, angiogenesis, and inflammation [20]. The relationship between excess estrogen exposure and GE has been unequivocally established [21]. There are conflicting literature data regarding E1 expression levels between normal and hyperplastic endometrium. All this is due to the fact that there are complex interactions between the cyclic endometrium and steroid hormones [21]. Some studies describe increased expression of ERa in HE without atypia compared to normal secretory endometrium [20]. On the contrary, -found no relationship between ERa or ERp expression and HE without atypia.



Progesterone receptors (PR) Progesterone counteracts the proliferative effects of estrogen by inducing secretory differentiation of the glandular and stromal endometrium and suppresses ER $\alpha$  expression. Progesterone exerts its action through progesterone receptors (PR), which also act through a ligand-activated transcription factor as do estrogen receptors [22]. Extensive studies using in vitro cell systems as well as genomic analyzes have identified PR as a gene regulated by estrogen [20]. PR isoforms: PR-A and PR-B are spatially and temporally controlled in endometrial compartments during the menstrual cycle. A significant association was found between HE recurrence without atypia, low stromal PRA, and high expression of glandular PRB.

### CONCLUSIONS

The relevance of the problem of endometrial hyperplastic processes does not lose its significance both from the standpoint of endometrial cancer prevention and from the standpoint of restoring and maintaining reproductive function. Thus, endometrial hyperplastic processes are a multifactorial disease, the formation of which involves the processes of hormone-dependent, hormone-independent endometrial cell proliferation, chronic inflammation, as well as genetic and epigenetic mechanisms. There is very little research data on the influence of genetic factors in the development of endometrial hyperplasia. Early diagnosis, prognosis of recurrence and response to conservative treatment is an opportunity not to be missed. Therefore, further research is needed in this area.

### References:

1. Al-Kaabi M, Noel K, Al-Rubai AJ. Evaluation of immunohistochemical expression of stem cell markers (NANOG and CD133) in normal, hyperplastic, and malignant endometrium. *J Med Life*. 2022 Jan;15(1):117-123. doi: 10.25122/jml-2021-0206.
2. Begum J, Samal R. A Clinicopathological Evaluation of Postmenopausal Bleeding and Its Correlation with Risk Factors for Developing Endometrial Hyperplasia and Cancer: A Hospital-Based Prospective Study. *J Midlife Health*. 2019 Oct-Dec;10(4):179-183. doi: 10.4103/jmh.JMH\_136\_18.
3. Behrouzi R, Barr CE, Crosbie EJ. HE4 as a Biomarker for Endometrial Cancer. *Cancers (Basel)*. 2021 Sep 23;13(19):4764. doi: 10.3390/cancers13194764.
4. Catena U, Della Corte L, Raffone A, Travaglino A, Lucci Cordisco E, Teodorico E, Masciullo V, Bifulco G, Di Spiezio Sardo A, Scambia G, Fanfani F. Fertility-sparing treatment for endometrial cancer and atypical endometrial hyperplasia in patients with Lynch Syndrome: Molecular diagnosis after

- immunohistochemistry of MMR proteins. *Front Med (Lausanne)*. 2022 Aug 25;9:948509. doi: 10.3389/fmed.2022.948509.
5. Chae-Kim J, Garg G, Gavrilova-Jordan L, Blake LE, Kim TT, Wu Q, Hayslip CC. Outcomes of women treated with progestin and metformin for atypical endometrial hyperplasia and early endometrial cancer: a systematic review and meta-analysis. *Int J Gynecol Cancer*. 2021 Dec;31(12):1499-1505. doi: 10.1136/ijgc-2021-002699.
  6. Chekhoeva A. N., Gabaraev G. M., Baroeva M. D. Clinical and diagnostic aspects and therapeutic tactics of endometrial hyperplastic processes from modern positions (literature review) // *Bulletin of new medical technologies*. Electronic edition. 2019. No. 4.
  7. Chen J, Cao D, Yang J, Yu M, Zhou H, Cheng N, Wang J, Zhang Y, Peng P, Shen K. Fertility-Sparing Treatment for Endometrial Cancer or Atypical Endometrial Hyperplasia Patients With Obesity. *front oncol*. 2022 Feb 18;12:812346. doi: 10.3389/fonc.2022.812346.
  8. Chen J, Cheng Y, Fu W, Peng X, Sun X, Chen H, Chen X, Yu M. PPOS Protocol Effectively Improves the IVF Outcome Without Increasing the Recurrence Rate in Early Endometrioid Endometrial Cancer and Atypical Endometrial Hyperplasia Patients After Fertility Preserving Treatment . *Front Med (Lausanne)*. 2021 Jul 27;8:581927. doi: 10.3389/fmed.2021.581927.
  9. Clarke MA, Long BJ, Sherman ME, Lemens MA, Podratz KC, Hopkins MR, Ahlberg LJ, Mc Guire LJ, Laughlin-Tommaso SK, Bakkum-Gamez JN, Wentzensen N. Risk assessment of endometrial cancer and endometrial intraepithelial neoplasia in women with abnormal bleeding and implications for clinical management algorithms. *Am J Obstet Gynecol*. 2020 Oct;223(4):549.e1-549.e13. doi: 10.1016/j.ajog.2020.03.032.
  10. Demakova N.A. Molecular and genetic characteristics of patients with endometrial hyperplasia and polyps // *Scientific results of biomedical research*. 2018. №2.
  11. Ikhtiyarova, G.A., Aslonova, M.Zh., Kurbanova, Z.Sh., Kalimatova, D.M. (2021) Promising diagnostic tools for endometriosis given the pathogenic role of genetic factors. *Russian Journal of Woman and Child Health*, 4 (1), DOI: 10.32364/2618-8430-2021-4-1-12-16.
  12. Lapina I.A., Dobrokhotova Yu.E., Ozolinya L.A., Chirvon T.G., Taranov V.V. An integrated approach to the management of patients with endometrial hyperplasia and metabolic syndrome // *Gynecology*. 2021. №1.

13. Luo L, Luo B, Zheng Y, Zhang H, Li J, Sidell N. Oral and intrauterine progestogens for atypical endometrial hyperplasia. *Cochrane Database Syst Rev.* 2018 Dec 4;12(12):CD009458. doi: 10.1002/14651858.CD009458.pub3.
14. Narzullaeva, N. S., Ixtiyarova, G. A., & Sh, B. A. (2022). Clinical and Immunological Aspects of Leiomyoma with Endometritis. *Central Asian Journal of Medical and Natural Science*, 3(4), 301-305.
15. Narzullayeva, N. S. (2022). INNOVATIVE METHODS OF DIAGNOSIS AND TREATMENT IN WOMEN WITH INFERTILITY ASSOCIATED WITH UTERINE FIBROIDS. *Journal of Pharmaceutical Negative Results*, 3313-3321.
16. Narzulloeva, N. S. (2022). Uterine Myoma: Optimization of Management and Immunomodulating Therapy. *INTERNATIONAL JOURNAL OF HEALTH SYSTEMS AND MEDICAL SCIENCES*, 1(4), 284-289. Kaprin A.D., Starinsky V.V., Shakhzodova A.O. Malignant neoplasms in Russia in 2019 (morbidity and mortality). *MNIOI them. PA Herzen - branch of the Federal State Budgetary Institution "NMITS Radiology" of the Ministry of Health of Russia*, 2020; 252.
17. Nazirova Z.M. Modern possibilities of diagnosing proliferative processes of the endometrium // *Economics and society*. 2020. No. 4 (71).
18. Orazov M.R., Mikhaleva L.M., Mullina I.A. Prediction of recurrent endometrial hyperplasia // *Difficult patient*. 2021. No. 7.
19. Orazov M.R., Mikhaleva L.M., Mullina I.A., Leffad L.M. Pathogenesis of recurrent endometrial hyperplasia without atypia // *Difficult patient*. 2021. №6.
20. Oripova, F.Sh. Ikhtiyarova, G.A., & Davlatov, S.S. (2021). Pathomorphological characteristics of the vaginal mucosa in experimental nonspecific vaginitis and various methods of treatment. *International Journal of Pharmaceutical Research*, 13(1), 761-765. doi: 10.31838/ijpr/2021.13.01.131 Navruzova, N. O., Karshiyeva, E. E., Ikhtiyarova, G. A., Hikmatova, N. I., Olimova, N. I., & Muminova, N. K. (2021). Clinical and laboratory markers forecasting of cervical diseases and its prevention. *Annals of the Romanian Society for Cell Biology*, 25(4), 13098-13110. Retrieved from [www.scopus.com](http://www.scopus.com).
21. Ponomarenko I.V., Demakova N.A., Altukhova O.B. Molecular mechanisms of development of endometrial hyperplastic processes // *Actual problems of medicine*. 2016. No. 19 (240).
22. Qurbonova, N. I., Khabibova, N. N., & Ikhtiyarova, G. A. (2020). Hygienic condition of the oral cavity and the level of hygienic knowledge of silk motor workers. *European Journal of Molecular and Clinical Medicine*, 7(3), 3027-3033. Retrieved from [www.scopus.com](http://www.scopus.com) Oripova, F. S., Ikhtiyarova, G. A., Shukurlaev, K.,



& Khamdamova, M. T. (2021). New methods of correction of inflammatory diseases of the genitalia (clinical and experimental study). Annals of the Romanian Society for Cell Biology, 25(4), 1865-1872. Retrieved from [www.scopus.com](http://www.scopus.com)

